

# Kinematics of the Shoulder Joint

Lädemann A<sup>1,2</sup> MD, Charbonnier C<sup>3</sup> PhD.

<sup>1</sup> Division of Orthopaedics and Trauma Surgery, La Tour Hospital, Geneva, Switzerland

<sup>2</sup> Faculty of Medicine, University of Geneva, Geneva, Switzerland

<sup>3</sup> Artanim Foundation, Medical Research Department, Geneva, Switzerland

Address correspondence and reprint requests to:

Alexandre Lädemann, PD-MD

Division of Orthopaedics and Trauma Surgery

La Tour Hospital

Av. J.-D. Maillard 3,

CH-1217 Meyrin, Switzerland

Telephone number: +41 22 719 75 55

Fax number: +41 22 719 60 77

E-mail address: alexandre.laedermann@gmail.com

**Disclaimer:** None author or their immediate family did receive any financial payments or other benefits from any commercial entity related to the subject of this article.

## **Summary**

This article presents the progress that has been made over the last past years in the understanding of shoulder kinematics. Dedicated patient-specific measurement techniques offer novel insights into the analysis of shoulder pathologies and open new horizons leading to improvement in comprehension and different treatments.

**Keywords:** Shoulder Kinematics Modeling; Biomechanics, Overhead Athletes; Instability; Impingement; Magnetic Resonance Imaging.

## **Introduction**

Shoulder function is the result of the complex interplay of the osseous, ligamentar, capsular and muscular structures of the shoulder girdle. Measuring the dynamic in vivo shoulder kinematics is crucial to better understand numerous pathologies, but remains a challenging problem due to its complicated anatomy, large range of motion and fast movements.

Various techniques for the measurement of in vivo scapular kinematics, including goniometer, radiography, magnetic resonance imaging (MRI), fluoroscopy and cutaneous marker-based methods (inertial sensors, electromagnetic or optoelectronic systems) are available. Unfortunately, the motion of the shoulder joints can hardly be explored with standard MRI or Computed Tomography (CT) because of the confined area of measurement and because with neither MRI nor CT it is possible to measure continuous dynamic motion. Fluoroscopy-based measurements provide sufficient accuracy for dynamic shoulder analysis, but use ionizing radiation. Intra-operative observations have been performed but remain limited by slow motion. Cutaneous marker-based methods are subject to inaccuracies due to the non-rigid markers placement on the skin resulting in soft tissue artefacts.

Nevertheless, the latter have been more studied and are the most used techniques for the measurement of scapular motion in the laboratory setting. Despite such efforts, no particular focus has been made in previous works on the precise description of glenohumeral kinematics. In particular, none of the current cutaneous markers-based techniques have reported translation values at the glenohumeral joint. This information is crucial to assess glenohumeral instability and to understand many motion-related disorders (e.g., shoulder impingement). One reason that might explain this void is that

current techniques either concentrate their efforts on the analysis of single shoulder bone (scapula) or focus on the description of humeral motion relative to the thorax rather than to its proximal bone. Yet, the present authors do believe it is important to consider the contribution of each bone in the estimation of glenohumeral kinematics by taking into account the whole kinematic chain of the shoulder complex from the thorax to the humerus through the clavicle and scapula, as it could globally help reduce soft tissue artefact errors.

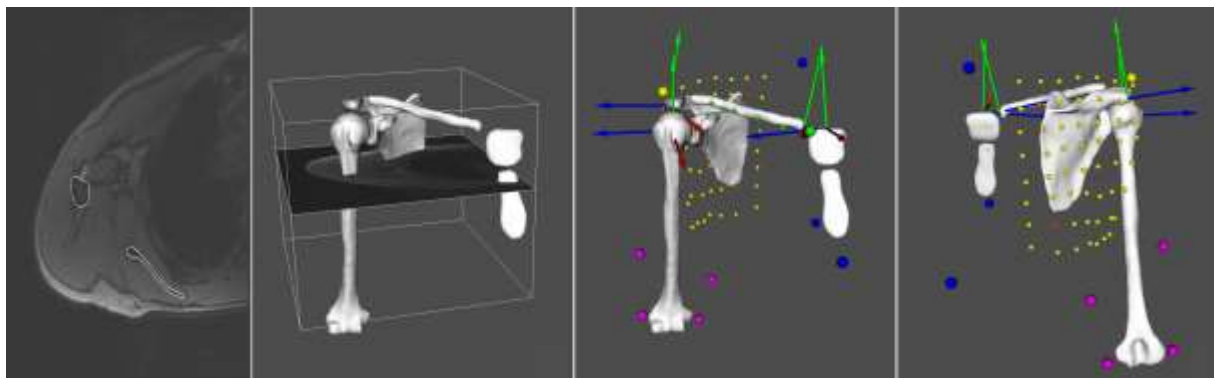


Figure 1: 3D reconstruction of the shoulder joints from MRI showing the bone coordinate systems [23] and the markers setup (small colored spheres).

We recently proposed a new measurement technique combining optical motion capture and 3D anatomical modelling from MRI. We developed a biomechanical model [1,2] based on a patient-specific kinematic chain using the shoulder 3D models reconstructed from patient's MRI data (Figure 1). Shoulder kinematics is then computed from the markers trajectories using a global optimization algorithm with loose constraints on joint translations. As a result, the motion of patient's shoulder 3D models can be visualized at each point of the movement (Figure 2). The accuracy of the model for glenohumeral orientation is within  $4^\circ$  for each anatomical plane and within 3 mm for glenohumeral translation [1,2], which has proven across the different

studies carried out so far to be acceptable for clinical use in the study of shoulder pathology.

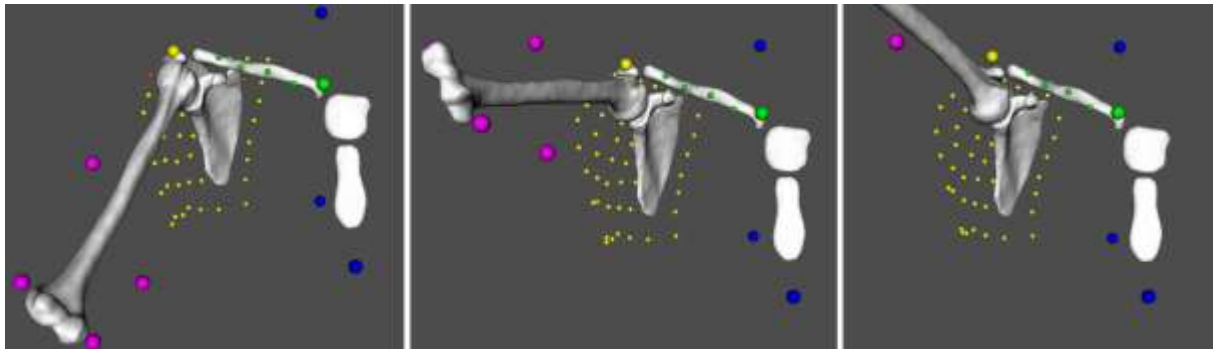


Figure 2: Example of kinematic animation of the shoulder joints during empty-can abduction.

## **Actual researches**

### *Impingements and instability*

Shoulder pain and injury are common, with a prevalence of 50% for certain age categories. The precise cause for these pains remains unclear, but it is believed to be the result of different factors (e.g., impingements (Gilles Walch's and Christopher Jobe's theories), anterior dynamic (Frank Jobe's theory) and posterosuperior static glenohumeral (Stephen Burkhart's theory) instability, scapular orientation, etc.).

A patient with an internal impingement will be treated differently if the etiology is a posteroinferior capsular contracture with resulting glenohumeral internal rotation deficit (which generally responds positively to a compliant posteroinferior capsular stretching program or to an arthroscopic selective posteroinferior capsulotomy and concomitant partial articular sided tendon avulsion (SLAP) lesion repair) [3] or a repetitive contact of the undersurface of the rotator cuff on the posterosuperior glenoid labrum (that can respond to debridement, glenoidplasty or derotational humeral osteotomy) [4-6].

Our research [7] has demonstrated that repetitive glenohumeral contact and hyperabduction could be the cause of posterior and posterosuperior labral lesions, as well as PASTA lesions of the posterosuperior cuff [8,9]. Indeed, as other authors [10], we have not been able to confirm the role in the impingement development relative to other culprits such as 1) static posterosuperior instability of glenohumeral contact point leading to torsional overload [3], or 2) anteroinferior instability due to gradual repetitive stretching of the anterior capsuloligamentous structures [11,12]. Our treatment paradigm has consequently changed and we nowadays promote more glenoidplasty rather than other surgical techniques.

One external impingement type is the subacromial impingement of the rotator cuff between the anterior acromion [13] or lateral acromion [14]. During abduction, we observed superior translation of the humeral head in relation to the glenoid, followed by inferior translation beyond 65°. Such superior and inferior translation confirmed previous observations [15,16]. Consequently, subacromial space decreased down to 65° and then increased progressively. Hence, anterior [13] and lateral [14] impingement could occur at the beginning of abduction [7] and not at or above 90° as previously believed [17].

We also evaluated dynamic posterior humeral head instability in relation to the glenoid during flexion [7]. A hypothesis for the development of posterior static subluxation described by Walch et al. [18] could be posterior subluxation during normal anterior elevation. At rest, the humeral head was slightly anteriorly translated. When forward flexion began, slight posterior translation was noted until 70° during normal anterior elevation. There was no posterior subluxation at any degree of flexion. Therefore, since no dynamic or physiologic posterior instability was observed, it is probably not responsible (at term) for static instability without hyperlaxity [7].

In presence of a rotator cuff lesion, articular cartilage pathology or instability, recommendations for design of a shoulder strength training protocol aim at avoiding or minimizing subacromial impingement, stress on the articular cartilages or labrum and excessive tendon elongation of the rotator cuff. Unfortunately, very limited objective data is at disposal to emit such recommendations. We hence assessed in another study the impact of the most common shoulder rehabilitation exercises (targeting 11 most frequently trained shoulder muscles or muscle groups) on subacromial space height, articular cartilages and labrum compression, and rotator cuff elongation. For each exercise, computer simulations [19,20] were performed using motion captured data (Figure 3). Results showed important variations in subacromial space height, cartilages and labrum compression and tendon elongation according to the type of strengthening exercise. This led us to classify those exercises and to better target the rehabilitation program according to the patient's pathology.

Finally, other studies concerning instability are currently under investigation thanks to our novel patient-specific measurement technique. For example, we still do not know if our shoulder stabilizations actually stabilize the joint or if they just prevent new episodes of dislocation. Indeed, a significant number of patients still experience apprehension after surgery. Even if other causes of persistent apprehension exists, such as brain sequelae that has recently been evoked [21,22], recurrent excessive anteroposterior translation could be another explanation. Such potential cause is under evaluation with our biomechanical shoulder model.

### **Future development**

These original methods open new horizons allowing, for instance, to better plan surgeries. A typical workflow would be to use the pre-operative radiological images

(MRI or CT scans) and to perform a 3D reconstruction of the patient's shoulder. Then, the 3D models could be simulated using a generic motion database of everyday activities in order to detect any abnormalities during motion. Moreover, the dynamic 3D simulations could assist surgeons by providing precise information on the surgical procedure to be executed (e.g., exact location and amount of the bone resection).

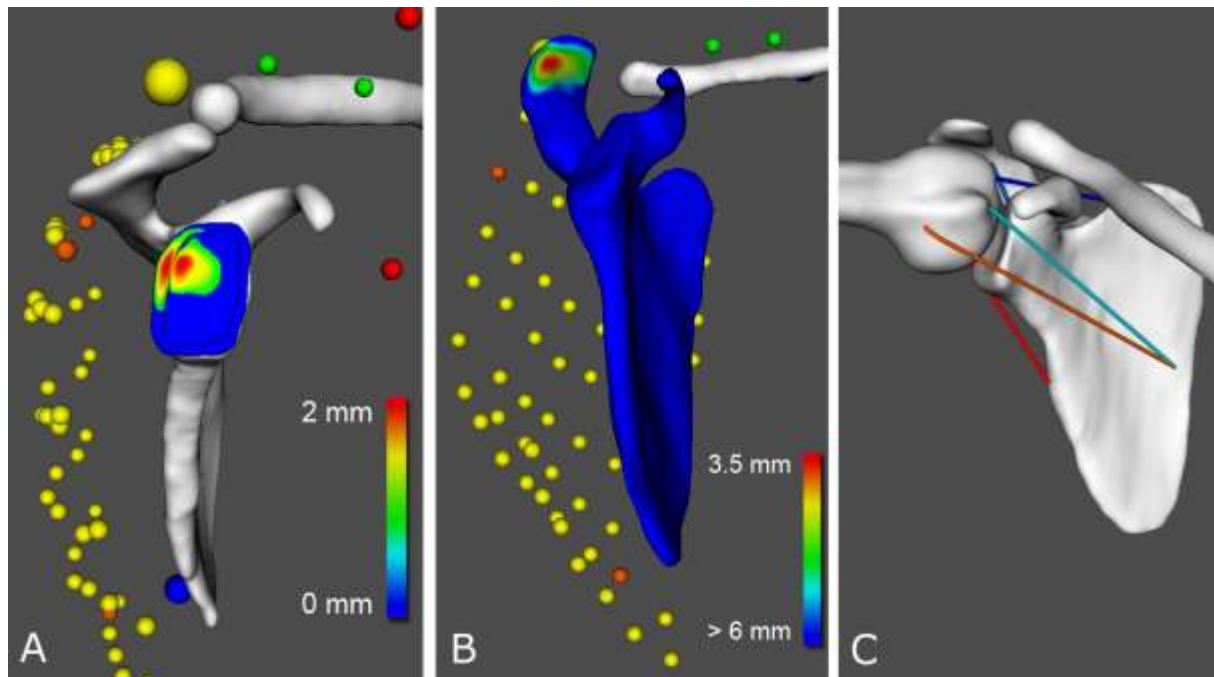


Figure 3: A) Visualization of the cartilage stress distribution during motion (red color = maximum compression). B) Visualization of the humero-acromial distance during motion (red color = minimum distance) for the evaluation of subacromial space height. C) Rotator cuff simulation (warm colors = elongation, cold colors = compression).

Other applications of these 3D technologies would be the development of software that will guide and help patients during shoulder rehabilitation. We will investigate the use of motion capture combined with interactive audiovisual feedback (e.g., virtual coach) to support rehabilitation training with rewarding mechanisms (gamification) and reliable monitoring of patient's progress. The visual display could be standard monitors (TV or projection), or more immersive technologies such as virtual reality headsets (e.g.,



Oculus Rift, Oculus VR, <https://www.oculus.com/en-us/>), which could help patients forgetting their pain and increasing their motivation to adhere to their treatment.

## **Conclusion**

Shoulder motion requires precise synchronous sequencing of the entire body. It is only by understanding the normal pattern of motion and muscle firing that an appreciation of potentially injurious deviations be realized. Recently published studies show that non-invasive, dynamic and in vivo techniques of evaluation, such as the combination of 3D anatomical models with motion capture, can provide valuable kinematic data at the glenohumeral joint. These technologies offer novel insights into the analysis of shoulder pathology and dysfunction leading to improvement in comprehension, and will consequently assist the clinician in successful diagnosis, treatment and prevention.

## References

1. Charbonnier C, Chague S, Kolo FC, Chow JC, Lädermann A (2014) A patient-specific measurement technique to model shoulder joint kinematics. *Orthopaedics & traumatology, surgery & research : OTSR*. doi:10.1016/j.otsr.2014.06.015
2. Charbonnier C, Chague S, Kolo FC, Lädermann A (2015) Shoulder motion during tennis serve: dynamic and radiological evaluation based on motion capture and magnetic resonance imaging. *International journal of computer assisted radiology and surgery* 10 (8):1289-1297. doi:10.1007/s11548-014-1135-4
3. Burkhart SS, Morgan CD, Kibler WB (2003) The disabled throwing shoulder: spectrum of pathology Part I: pathoanatomy and biomechanics. *Arthroscopy* 19 (4):404-420. doi:10.1053/jars.2003.50128
4. Levigne C, Garret J, Grosclaude S, Borel F, Walch G (2012) Surgical technique arthroscopic posterior glenoidplasty for posterosuperior glenoid impingement in throwing athletes. *Clin Orthop Relat Res* 470 (6):1571-1578. doi:10.1007/s11999-012-2294-7
5. Riand N, Boulahia A, Walch G (2002) [Posterosuperior impingement of the shoulder in the athlete: results of arthroscopic debridement in 75 patients]. *Rev Chir Orthop Reparatrice Appar Mot* 88 (1):19-27
6. Riand N, Levigne C, Renaud E, Walch G (1998) Results of derotational humeral osteotomy in posterosuperior glenoid impingement. *Am J Sports Med* 26 (3):453-459
7. Lädermann A, Chague S, Kolo FC, Charbonnier C (2014) Kinematics of the shoulder joint in tennis players. *Journal of science and medicine in sport / Sports Medicine Australia*. doi:10.1016/j.jsams.2014.11.009
8. Jobe CM (1996) Superior glenoid impingement. *Current concepts. Clin Orthop Relat Res* (330):98-107

9. Walch G, Boileau P, Noel E, Donell ST (1992) Impingement of the deep surface of the supraspinatus tendon on the posterosuperior glenoid rim: An arthroscopic study. *J Shoulder Elbow Surg* 1 (5):238-245. doi:10.1016/S1058-2746(09)80065-7
10. Halbrecht JL, Tirman P, Atkin D (1999) Internal impingement of the shoulder: comparison of findings between the throwing and nonthrowing shoulders of college baseball players. *Arthroscopy* 15 (3):253-258
11. Davidson PA, Elattrache NS, Jobe CM, Jobe FW (1995) Rotator cuff and posterior-superior glenoid labrum injury associated with increased glenohumeral motion: a new site of impingement. *J Shoulder Elbow Surg* 4 (5):384-390
12. Jobe CM (1995) Posterior superior glenoid impingement: expanded spectrum. *Arthroscopy* 11 (5):530-536
13. Neer CS, 2nd (1972) Anterior acromioplasty for the chronic impingement syndrome in the shoulder: a preliminary report. *J Bone Joint Surg Am* 54 (1):41-50
14. Nyffeler RW, Werner CM, Sukthankar A, Schmid MR, Gerber C (2006) Association of a large lateral extension of the acromion with rotator cuff tears. *J Bone Joint Surg Am* 88 (4):800-805. doi:10.2106/JBJS.D.03042
15. Matsuki K, Matsuki KO, Yamaguchi S, Ochiai N, Sasho T, Sugaya H, Toyone T, Wada Y, Takahashi K, Banks SA (2012) Dynamic in vivo glenohumeral kinematics during scapular plane abduction in healthy shoulders. *The Journal of orthopaedic and sports physical therapy* 42 (2):96-104. doi:10.2519/jospt.2012.3584
16. Massimini DF, Boyer PJ, Papannagari R, Gill TJ, Warner JP, Li G (2012) In-vivo glenohumeral translation and ligament elongation during abduction and abduction with internal and external rotation. *Journal of orthopaedic surgery and research* 7:29. doi:10.1186/1749-799X-7-29

17. Harrison AK, Flatow EL (2011) Subacromial impingement syndrome. *J Am Acad Orthop Surg* 19 (11):701-708
18. Walch G, Ascani C, Boulahia A, Nove-Josserand L, Edwards TB (2002) Static posterior subluxation of the humeral head: an unrecognized entity responsible for glenohumeral osteoarthritis in the young adult. *J Shoulder Elbow Surg* 11 (4):309-314. doi:10.1067/mse.2002.124547
19. Charbonnier C, Kevelham B, Chagué S, Lädermann A, Ziltener J, Hoffmeyer P, Holzer N (June 2015) Impact of Shoulder Strengthening Exercises on the Shoulder Joint. Paper presented at the 33rd International Conference on Biomechanics in Sports, Poitiers, France,
20. Charbonnier C, Kevelham B, Chagué S, Lädermann A, Ziltener J, Hoffmeyer P, Holzer N (June 2015) A Simplified Technique To Estimate Rotator Cuff Elongation During Complex Shoulder Motion. Paper presented at the 29th International Congress of Computer Assisted Radiology and Surgery, Barcelona, Spain,
21. Cunningham G, Zanchi D, Emmert K, Kopel R, Van De Ville D, Lädermann A, Haller S, Hoffmeyer P (2015) Neural Correlates of Clinical Scores in Patients with Anterior Shoulder Apprehension. *Medicine and science in sports and exercise*. doi:10.1249/MSS.0000000000000726
22. Haller S, Cunningham G, Lädermann A, Hofmeister J, Van De Ville D, Lovblad KO, Hoffmeyer P (2014) Shoulder apprehension impacts large-scale functional brain networks. *AJNR American journal of neuroradiology* 35 (4):691-697. doi:10.3174/ajnr.A3738
23. Wu G, van der Helm FC, Veeger HE, Makhsous M, Van Roy P, Anglin C, Nagels J, Karduna AR, McQuade K, Wang X, Werner FW, Buchholz B (2005) ISB recommendation on definitions of joint coordinate systems of various joints for the

reporting of human joint motion--Part II: shoulder, elbow, wrist and hand. J Biomech  
38 (5):981-992