

An integrated platform for hip joint osteoarthritis analysis

Design, implementation and results

Caecilia Charbonnier · Nadia Magnenat-Thalmann · Christoph Becker · Pierre Hoffmeyer · Jacques Menetrey

Received: date / Accepted: date

Abstract *Purpose* We present a software designed to improve hip joint osteoarthritis (OA) understanding using 3D anatomical models, magnetic resonance imaging (MRI) and motion capture.

Methods In addition to a standard static clinical evaluation (anamnesis, medical images examination), the software provides a dynamic assessment of the hip joint. The operator can compute automatically and in real-time the hip joint kinematics from optical motion capture data. From the estimated motion, the software allows for the calculation of the active range of motion, the congruency and the center of rotation of the hip joint, and for the detection and localization of the femoroacetabular impingement (FAI) region. All these measurements cannot be performed clinically. Moreover, to improve the subjective reading of medical images, the software provides a set of 3D measurement tools based on MRI and 3D anatomical models to assist and improve the analysis of hip morphological abnormalities. Finally, the software is driven by a medical ontology to support data storage, processing and analysis.

Results We performed an in vivo assessment of the software in a clinical study conducted with 30 professional ballet dancers, a population who is at high-risk of developing

OA. We studied the causes of OA in this selected population. Our results show that extreme motion exposes the morphologically “normal” dancer’s hip to recurrent superior or posterosuperior FAI and to joint subluxation.

Conclusion Our new hip software includes all the required materials and knowledge (images data, 3D models, motion, morphological measurements, etc.) to improve orthopedists’ performances in hip joint OA analysis.

Keywords Hip joint · Osteoarthritis · 3D Simulation · Hip Motion · Ontology

1 Introduction

Osteoarthritis (OA) is among the leading causes of chronic musculoskeletal disabilities and typical symptoms include functional impairment, pain, stiffness and limited motion. OA commonly affects large weight-bearing joints such as the hips and knees. In some cases, early hip OA could be explained by femoroacetabular impingements (FAI) which occur when there is an abutment conflict between the proximal femur and the acetabular rim. Two types of FAI have been distinguished: the cam FAI caused by a non-spherical head at the femoral head-neck junction [2, 15–17, 24, 28] and the pincer FAI due to acetabular overcoverage [2, 10, 16, 17, 24, 28] or acetabular retroversion [25]. These morphological abnormalities induce early degenerative lesions of the cartilages and superior labrum [27, 28]. FAI of the cam/ pincer type cannot explain observed OA in hips with normal morphology. However, changes in the movement and alignment of the hip (e.g., subluxation) could be potential causes of the development of early OA in the young active adult. Indeed, sporting activities that require repetitive and extreme movements (e.g., dancers, gymnasts, etc.) have been thought to result in labral tears [3, 9, 14, 19–22].

C. Charbonnier
MIRALab - University of Geneva
7, route de Drize, 1227 Carouge, Switzerland
Tel.: +41-22-3790953
Fax: +41-22-3790079
E-mail: charbonnier@miralab.unige.ch

N. Magnenat-Thalmann
MIRALab - University of Geneva, Switzerland

C. Becker
University Hospital of Geneva, Department of Radiology, Switzerland

P. Hoffmeyer · J. Menetrey
University Hospital of Geneva, Department of Orthopedic Surgery,
Switzerland

<p>Compatibility</p> <ul style="list-style-type: none"> • Microsoft Windows compatible application • No installation required (simple executable) • DICOM file format support • Imports/ exports 3D scenes, VTK, OBJ or STL • Exports videos, TIFF or AVI • Export images, JPG or TIFF 	<p>(opacity, appearance, resolution, etc.)</p> <ul style="list-style-type: none"> • User-friendly interface for easy manipulation of MRI volumes • Programmable 3D cameras with animation scripts • 3D annotations 	<ul style="list-style-type: none"> • Import motion capture data (markers trajectories), CSM • Import dynamic MRI data • Export estimated bone motion from markers trajectories • User-friendly interface for easy interaction with motion capture-related components (virtual skeleton, markers, etc.) • Hip joint subluxation amount computation and export • Hip joint range of motion computation and export 	<ul style="list-style-type: none"> • Penetration depth computation and export
<p>Image and 3D display</p> <ul style="list-style-type: none"> • Interactive MRI viewer with brightness/ contrast adjustment • Interactive 3D window with real-time navigation • User-friendly interface for controlling the display of 3D models 	<p>Image analysis tools</p> <ul style="list-style-type: none"> • Acetabular version computation • Acetabular depth computation • Femoral alpha neck angle computation 	<p>FAI detection tools</p> <ul style="list-style-type: none"> • Automatic detection and localization of FAI regions 	<p>Ontology features</p> <ul style="list-style-type: none"> • Anatomical and functional ontology framework for the musculoskeletal system • Browsing and querying support
	<p>Motion analysis tools</p> <ul style="list-style-type: none"> • Hip joint's center and bone's coordinates system computation 		

Fig. 1 Summary of the features available in VisualHuman.

The diagnosis and pre-operative planning of hip OA is generally based on a clinical evaluation of the hip joint, which includes anamnesis (localization of pain, determination of the joint range of motion), Computed Tomography (CT) or Magnetic Resonance Imaging (MRI) examination and morphological analysis of the bony structures. Clinicians have therefore no technical means to evaluate *in vivo* dynamic pathologies of the hip joint. We believe that dynamic *in vivo* 3D modeling will allow the identification of movements that could lead to hip pathologies and contribute to improve knowledge about patterns leading to OA. For instance, we have shown in previous works preliminary earnings of using MRI data to reconstruct and visualize in 3D patient-specific hip joint models [12, 26], and motion capture data to detect pathological hip conditions (e.g., FAI, subluxation) while visualizing the joint in motion [4–8].

We developed an integrated platform dedicated to the hip joint OA analysis because the integration and combination of precise image-based morphological measurements, functional hip joint simulation (which may include motion capture or dynamic MR imaging) and 3D reconstruction are highly challenging and beneficial for the orthopedists in routine practice. Moreover, examination performance is currently limited to a static assessment of the joint and is reader-dependent because findings are subjective (e.g., morphological measurements). Additionally, there is a lack of validated non-invasive methods to ascertain impingement dur-

ing motion. Automated 3D FAI detection and localization of damaged areas within the chondrolabral structures are hence needed. This paper describes the software design, the implementation of hip-specific analysis tools, and the results obtained using this software in a clinical study conducted with professional ballet dancers.

2 Materials and methods

2.1 Software design

We developed a hip-dedicated software known as “VisualHuman”. This software was designed for Microsoft Windows systems, and written in conventional C++ using Microsoft Visual Studio, as this environment allows for flexible and rapid application development. Development was based on the VTK open source toolkit [31], which enabled us to quickly include medical images compatibility (e.g., DICOM), a suit of 3D interaction widgets, as well as visualization and image processing components. The platform is driven by a medical ontology that takes into account not only the anatomy, but also the functionality of the musculoskeletal system. This ontology contains the core medical knowledge and acts as a medical interpreter between the user and the data (see Sect. 2.5). A summary of the features available

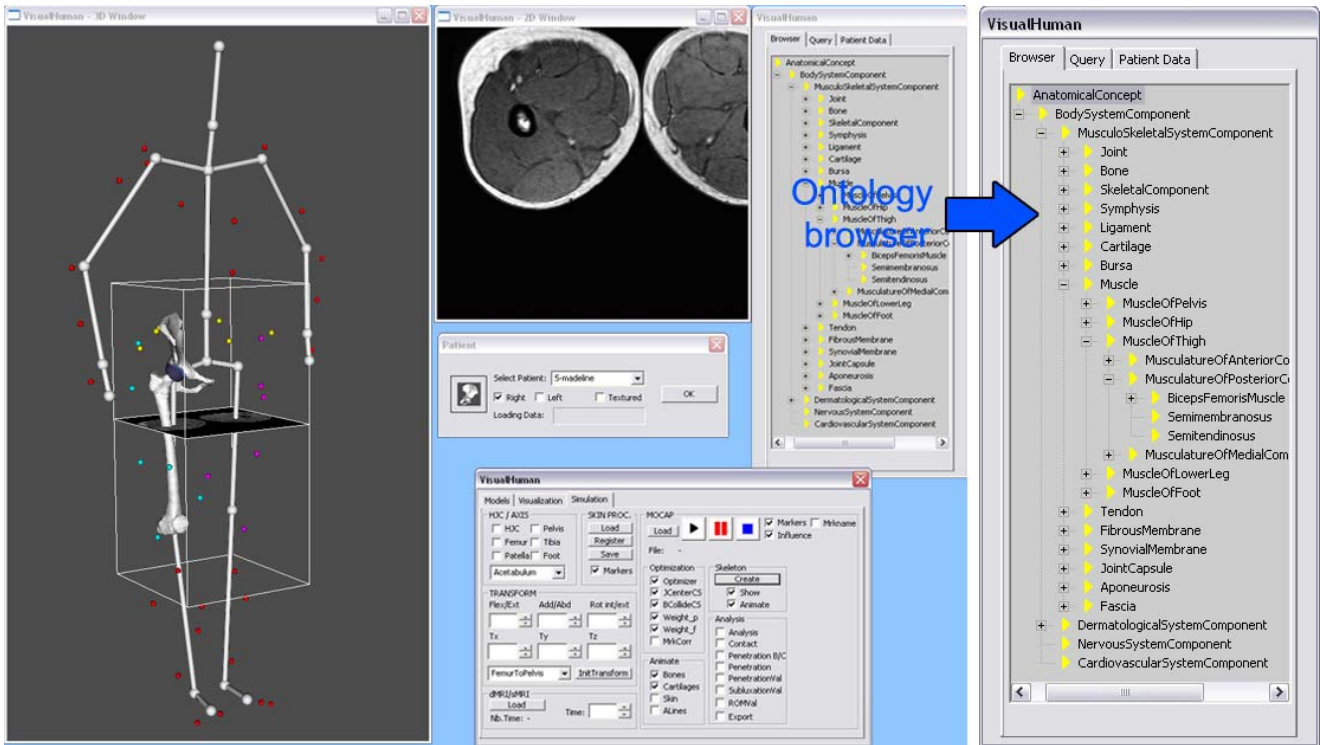


Fig. 2 Screenshot of the software’s graphical user interface. In the *middle*, a panel allows for the selection of the patient to be analyzed and for the loading of its corresponding data. On the *left*, a large resizable window displays the loaded 3D structures and objects, such as the bones and cartilages of the patient, the MRI volume(s) or motion capture-related components (virtual skeleton, markers). On the *middle top*, a resizable window displays MRI slices and allows for the 2D interaction with images. In the *bottom left-hand corner*, several panels provide access to the visualization and simulation tools. The ontology is available for browsing in the *right* panel (see also enlarged image on the *right*).

in VisualHuman is provided in Figure 1 and a screenshot of the software’s graphical user interface is shown in Figure 2.

2.2 Image analysis

Our framework is based on the MRI modality. We chose MRI technique because it is not invasive, versatile and able to image simultaneously soft and bony tissues. In a previous step, MRI were used to reconstruct patient-specific 3D models of the hip joint (including pelvis, femur, cartilages, and labrum) using a segmentation procedure [12,26]. In this software, MRI in combination with 3D anatomical models are devoted to support the analysis of hip morphological abnormalities. Under the collaboration with radiologists, a set of measurement tools was therefore implemented in 3D, improving the subjective reading of medical images. The morphology of the hip is well described by selected anatomical parameters:

One important parameter is the computation of the acetabular version that identifies the orientation of the opening of the acetabulum. This measure is an indicator of pincer FAI [24]. We have implemented the standard measurement method from [25], in a fully automatic fashion. It is based on the angle between the sagittal direction and lines drawn be-

tween the anterior and posterior acetabular rim, at different heights (Fig. 3a). The angle is considered as positive when inclined medially to the sagittal plane (anteversion) and negative when inclined laterally to the sagittal plane (retroversion). Normal hips are anteverted. Contrary to [25], we use the anatomical axis of the 3D reconstruction of the acetabulum (i.e., the pelvic frame, see Sect. 2.3) instead of a reference axis based on CT or MRI slices. Thus, our results are independent from the patient positioning in the magnet bore.

Another indicator of pincer FAI is the acetabular depth [24]. If the acetabulum is too deep (i.e., *coxa profunda*), pincer FAI are more favorable to occur. The depth of the acetabulum is defined as the distance in millimeter between the center of the femoral head (O) and the line $AR - PR$ connecting the anterior (AR) and posterior (PR) acetabular rim (Fig. 3b). The value is considered as positive and normal if O is lateral to the line $AR - PR$. This measure requires an accurate identification of O . Thus, our method automatically fits a sphere to approximate the femoral head, so as to simplify and reduce errors in typical manual measurement.

A standard parameter related to the femur geometry is the femoral alpha (α) neck angle that is used for detecting non-spherical shapes (bumps) of the femoral head. Bumps are factor of cam FAI [24]. The α angle is measured in 8 positions around the femoral neck using radially reformat-

ted images superimposed on the 3D reconstruction model to make sure being in the femoral neck axis. We have implemented the measurement method from [23]. The α angle is being defined by the angle formed by the line $O - O'$ connecting the center of the femoral head (O) and the center of the femoral neck (O') at its narrowest point, and the line $O - P$ connecting O and the point P where the distance between the bony contour of the femoral head and O exceeds the radius (r) of the femoral head (Fig. 3c). Deviation from the normal geometry is usually associated with larger α angles ($> 55^\circ$). As for the acetabular depth, this measure requires an accurate identification of O . Therefore, the same method is used to automatically fit a sphere approximating the femoral head.

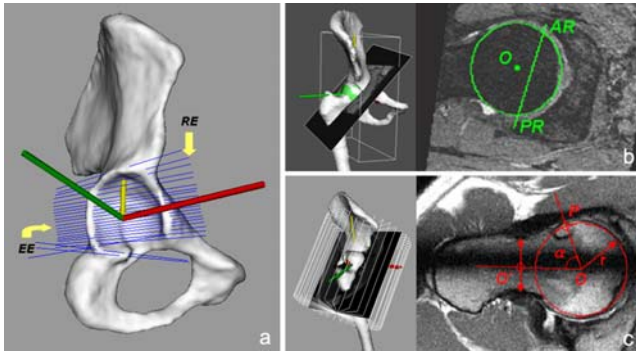


Fig. 3 a) Computation of the acetabular version based on 3D reconstruction; roof edge (RE) and equatorial edge (EE) are lines drawn between the anterior and posterior acetabular edges, defining the orientation of the acetabular opening proximally and at the maximum diameter of the femoral head respectively (arrows) b) Definition of the acetabular depth (right) on a transverse oblique MR image (left) c) Definition of the α angle (right) on a radial MR image (left), illustrating a cam type morphology ($\alpha = 85^\circ$).

To perform these measurements using the software, the operator only has to select the appropriate MRI volume and interactively place landmarks on the images. Measuring in 3D space (that is independently from the patient positioning in the magnet bore) along with the automatic detection of the center of the femoral head, has the advantage to provide more accurate, reader-independent, reproducible and repeatable results.

2.3 Motion analysis

The main idea of the proposed software is that 3D functional models can provide valuable insight into the understanding of hip pathology. To this end, the software integrates a module to compute the hip joint kinematics from optical motion capture data. This module only requires a standard file of recorded markers' trajectories (CSM file) and enables the operator to compute automatically and in real-time the ac-

tive range of motion (ROM), the congruency and the center of rotation of the hip joint. All these measurements cannot be performed clinically.

From the motion capture data, the hip joint kinematics is accurately estimated using a previously developed and validated optimized fitting algorithm [4, 7, 8] which reduces parasitic markers movements due to muscle activities. The movement of the skeleton (based on a ball and stick representation) is also estimated to assist the analysis and visualization of the motion. Figure 4 shows examples of computed postures.

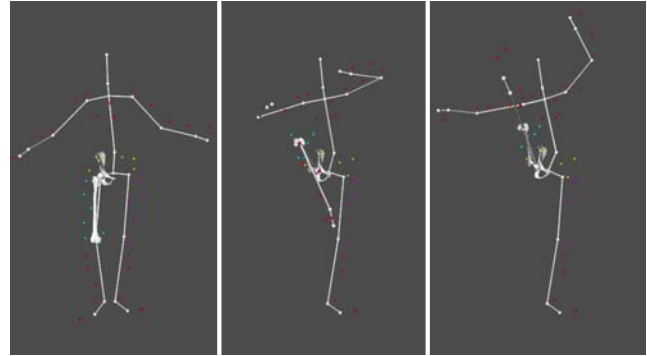


Fig. 4 Examples of computed postures: dancing movement animation (développé devant).

The ROM and congruency of the hip joint are calculated using the patient's bony 3D models and two coordinate systems (one for the femur and one for the pelvis). We use the definitions proposed by the Standardization and Terminology Committee of the International Society of Biomechanics [32] to report joint motion in an intra- and inter-patient repeatable way. The pelvic and femoral coordinates systems are first evaluated from anatomical landmarks defined on the reconstructed surface of the hip and femur bones. Then, these axes standardize the joint coordinate system. Thus, given the computed bone positions from the motion capture data, normalized hip joint angles and translations are determined at each point of the movement, using the two bone coordinate systems. Eventually, to determine the position of the hip joint center (HJC), the software uses a functional method [11] which entails the simulation of the hip and femur bones 3D models during a circumduction motion pattern. The computed values (ROM, subluxation and HJC) can be saved to disk for further analysis.

Instead of motion capture, the operator can perform the same measurements (ROM and subluxation) using dynamic MRI data. However, an additional step is required in order to process the MR series and to track the bones trajectories [13].

2.4 FAI detection and localization

From the motion capture data, the software allows for the automatic detection and calculation in real-time of individual impingement zones over the full range of motion. While visualizing the patient's hip joint in motion, a collision detection algorithm is used to virtually locate abnormal contacts between the proximal femur and the labrum [4, 7, 8]. To estimate the overall FAI, the surface-to-surface distance (i.e., penetration depth) is computed. This distance represents the topographic extent of the labrum compression and is reported in millimeter. Moreover, the visualization of the penetration depth distribution on the surface of the labrum is represented using a color table (Fig. 5).

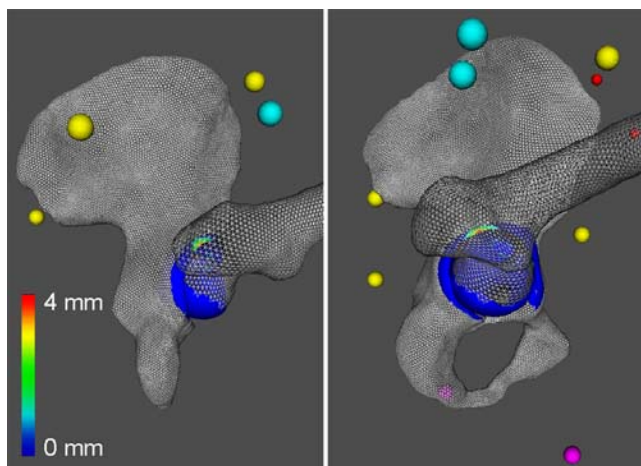


Fig. 5 Visualization of the FAI region during motion (posterior and lateral views). The colors represent the penetration depth distribution.

2.5 Semantic engine

The software is driven by a medical ontology that takes into account not only the anatomy, but also the functionalities of the musculoskeletal system. Our model comprises 825 classes and 1244 instances, representing the concepts and their relationships that relate to the structural anatomy of the human musculoskeletal system at the macroscopic level. Some instances contain specific attributes referring to relational (e.g., anatomical relationships such as organ's attachments) or kinematical (e.g., joint center, joint axis, etc.) parameters so as to define the functional properties of the entity. Moreover, all entities are linked to a 3D model. The software can hence automatically associate the concept to its concrete representation.

The ontology was designed with Protégé [30] and subsequently exported into an XML file. To connect the generated XML file with our software, we use Berkeley DB XML [29]. This solution allows us to read the XML file via a C++ API

in order to visualize our medical ontology directly in the software and to create queries.

The ontology contains the core medical knowledge and constitutes the interface between the software and the medical interpretation of the data. For instance, to visualize the 3D models, the operator browses the ontology classes (i.e., selection from the ontology browser, see Fig. 2) which dynamically loads the 3D models. The ontology can be interactively navigated in real-time, thus enabling e.g., interesting assimilation of the articulations (e.g., for training of medical students), as well as the display of the models properties (i.e., by querying the elements of the ontology). The ontology also offers a support for data fusion and completion and automates the data transfer and processing. As all the acquisition modalities and measurements will not be systematically available at clinical sites, the ontology stores generic anatomical and functional parameters, which provides easy access for references. These generic parameters are then adapted as best as possible to the patient characteristics. Finally, the ontology stores the results of the morphological measurements and analysis of the patient data, which should allow statistical assessment for subject comparisons and longitudinal studies.

Additional information can be easily added to the ontology, i.e., surgical information could be introduced (e.g., estimating the bone resurfacing for corrective surgery in the case of cam FAI or bone resection, prosthesis alignment, etc.), to assist the planning and post-operative phases.

2.6 In vivo assessment

We performed an in vivo assessment of the software in a clinical study conducted with professional ballet dancers, a population who is at high-risk of developing OA [3, 19, 14, 18]. Thirty female dancers (60 hips) aged between 18 and 39 years (mean, 24.6 years) were recruited. The volunteers were all professional and performed classical ballet and contemporary dance. They were excluded if they reported a prior surgery of the hip. All subjects underwent MR imaging and a complete physical examination of the hip. Ten of them were motion captured during 6 dancing movements: grand plié, développé à la seconde, développé devant, grand écart latéral, grand écart facial and arabesque. The study was approved by our Institutional Review Board and informed consent was required from each volunteer.

For each dancer, both hips were assessed using the software by two experienced orthopedic surgeons. The 3D models of the hip joints and the respective cartilages were first loaded in the software thanks to the ontology browser. Using the MRI data, the shape of the bones were analyzed and results of the morphological measurements were stored in the ontology. The hip joints were then simulated according to recorded motion capture data. The ROM and congruency

Table 1 Mean \pm SD range of motion of the hip during dancing's movements.

Angles	Mean \pm SD ($^{\circ}$)
Flexion /	84.44 \pm 22.76
Extension	31.60 \pm 7.95
Abduction /	42.42 \pm 20.49
Adduction	0
IR /	25.49 \pm 11.83
ER	15.59 \pm 11.57

of the hip joints were computed and FAI were detected automatically. Results of the simulation (ROM, subluxation and penetration depth) were finally saved to disk. The overall assessment for each subject (2 hips) required 20-25 minutes on a standard PC, which was according to the two orthopedic surgeons clinically applicable in routine practice.

3 Results

3.1 Imaging data

The normality of the 30 dancers' hips was measured using the 3D morphological tools. The results revealed a mean \pm standard deviation (SD) acetabular depth of 7.5 ± 1.7 mm, a mean \pm SD acetabular version of $7.5^{\circ} \pm 4.1$, a mean \pm SD α angle in anterior position of $45.5^{\circ} \pm 5.3$ and a mean \pm SD α angle in anterosuperior position of $46.7^{\circ} \pm 6.7$. For the α angles, only the measures in anterior and anterosuperior positions are reported, since they are the more significant. From our results, no cam or pincer morphologies were thus detected.

In addition to the morphological analysis, two musculoskeletal radiologists analyzed all MR images. Cartilage lesions were significantly located in the superior (64%) part of the acetabulum. Labral lesions were diagnosed mostly in superior (48%) and posterosuperior (32%) positions. No intraarticular contrast material was injected in the dancers' hips during MR imaging, because of the invasiveness of this procedure. However, the radiologists estimated that the reliability of the current findings was at least 60%.

3.2 Motion data

Using the software, the ROM and congruency of the hip joint were quantified for the 10 dancers and for the 6 recorded dancing movements. FAI were also investigated. The following two criteria were applied: (1) Whenever there is subluxation, there is loss of hip joint congruence. Thus, any femoroacetabular translation was considered as detrimental to the joint; (2) Knowing that the labrum has an average height of 5 mm, FAI were considered when the labrum compression (i.e., penetration depth) was greater than 2 mm,

since this amount could be potentially damageable for the joint when observed repetitively. The motion study stressed the following findings:

As shown in Table 1, dancing involves intensive hip flexion and abduction combined with rotation. It is important to note that the ROM was measured independently of the major anatomical planes (i.e., sagittal, transverse, frontal planes), thanks to the two bone coordinate systems (see Sect. 2.3).

The frequency of FAI and subluxation, and the amount of penetration depth and femoroacetabular translations varied with the type of movement (Table 2). Four dancing movements (*développé à la seconde*, *grand écart facial*, *grand écart latéral* and *grand plié*) seemed to create significant stress in the hip joint, according to the observed high frequency of impingement and amount of subluxation. 92% of the computed zones of FAI were located in the superior (44%) or posterosuperior (48%) part of the acetabulum. The simulation results were hence relevant with respect to the MRI findings.

4 Conclusion

Our main objective in designing the software was to support orthopedists with the analysis of hip motion in order to detect pathological hip conditions (e.g., FAI, subluxation). We aimed at providing clinicians with new dynamic information (which is not available yet in classic clinical approaches) to better understand hip motion and their potential risk for developing OA. For instance, the automated FAI detection tool opens up new possibilities, such as helping to plan bone resection areas of the femoral neck in cases of FAI. Eventually, the software improves the accuracy of the morphological measurements and the medical ontology offers a support for data storage, processing and analysis.

To validate the software on a large range of motion, we chose to study ballet dancers which led us to highlight interesting findings: (1) the dancers' hips were morphologically normal; (2) extreme motion was possible thanks to a combination of three articular motion patterns; (3) FAI and subluxation were often observed in typical ballet positions, suggesting that these movements should be limited in frequency; (4) the computed zones of FAI were mainly located in the superior or posterosuperior area of the acetabulum and

Table 2 Frequency of impingement and subluxation, and amount (mean \pm SD) of penetration depth and subluxation by movement.

Movements	Frequency of FAI	Frequency of subluxation	Penetration depth (mm)	Subluxation (mm)
Arabesque	0%	0%	0	0
Développé devant	27%	0%	2.5 \pm 1.2	0
Développé à la seconde	44%	22%	3.38 \pm 2.0	4.32 \pm 1.17
Grand écart facial	63%	38%	3.87 \pm 2.55	3.05 \pm 1.38
Grand écart latéral (front leg)	73%	27%	2.07 \pm 1.9	5.0 \pm 1.54
Grand écart latéral (back leg)	25%	13%	1.11 \pm 1.33	3.15 \pm 0
Grand plié	44%	13%	2.58 \pm 1.88	3.02 \pm 2.28

this was correlated with the MRI findings. This localization is in fact unusual because resulting chondrolabral damages due to FAI such as of the cam or pincer type are generally located in the anterosuperior position [1, 2, 27, 28]. In conclusion, we think that dancing implies a new superior/ posterosuperior FAI due to extreme movements.

Thanks to this software, the understanding of the hip OA is improved. All the required materials and knowledge (images data, 3D models, motion, morphological measurements, etc.) are interactively and quickly accessible to the operator providing support to diagnosis, but also to teaching and training.

Future work should include physically-based simulations of the chondrolabral structures to account for the mechanical properties and deformations of the soft tissues under loads. This could be integrated in a next software version to contribute to a better evaluation of the pathology and subsequent treatment.

Acknowledgements This work was supported by the Co-Me project funded by Swiss National Research Foundation and by the FOCUS K3D project (FP7-ICT-2007-214993) funded by the European Union. We would like to thank Jérôme Schmid, Lazhari Assassi, Dr. Benjamin Gilles, Dr. Frank Kolo-Christophe, Dr. Victoria Duthon, Marlène Arévalo and Nedjma Cadi for their collaboration. We are also grateful to all volunteers for the ballet of the Grand Théâtre de Genève to have accepted to take part in the study.

References

1. Beaulé, P., Zaragoza, E., Motamedi, K., Copelan, N., Dorey, F.: Three-dimensional computed tomography of the hip in the assessment of femoroacetabular impingement. *J Ortho Res* **23**(6), 1286–1292 (2005)
2. Beck, M., Kalhor, M., Ganz, R.: Hip morphology influences the pattern of damage to the acetabular cartilage: femoroacetabular impingement as a cause of early osteoarthritis. *J Bone Joint Surg Br* **87**, 1012–1018 (2005)
3. Binningsley, D.: Tear of the acetabular labrum in an elite athlete. *Br J Sports Med* **37**, 84–88 (2003)
4. Charbonnier, C., Assassi, L., Volino, P., Magnenat-Thalmann, N.: Motion study of the hip joint in extreme postures. *Vis Comput* **25**(9), 873–882 (2009)
5. Charbonnier, C., Kolo-Christophe, F., Duc, S., Pfirrmann, C., Menetrey, J., Duthon, V., Magnenat-Thalmann, N., Becker, C., Hoffmeyer, P.: Extreme motion as a potential initiator of hip osteoarthritis. *Swiss Med Wkly Suppl.* **173**, 139(23-24), 18S (2009)
6. Charbonnier, C., Kolo-Christophe, F., Duthon, V., Magnenat-Thalmann, N., Becker, C., Hoffmeyer, P., Menetrey, J.: Professional dancer's hip: A motion capture study. In: *Trans Orthop Res Soc. New Orleans, Louisiana* (2010)
7. Charbonnier, C., Lyard, E., Magnenat-Thalmann, N.: Analysis of extreme hip motion in professional ballet dancers. In: *Proc of the 10th International Symposium on 3D Analysis of Human Movement [CD-ROM]. Amsterdam, Netherlands* (2008)
8. Charbonnier, C., Schmid, J., Kolo-Christophe, F., Magnenat-Thalmann, N., Becker, C., Hoffmeyer, P.: Virtual hip joint: from computer graphics to computer-assisted diagnosis. In: *Eurographics 2009 - First Medical Prize*, pp. 1–4. Eurographics Association, Munich, Germany (2009)
9. Clohisy, J., Knaus, E., Hunt, D., Leshner, J., Harris-Hayes, M., Prather, H.: Clinical presentation of patients with symptomatic anterior hip impingement. *Clin Orthop Rel Res* **467**, 638–644 (2009)
10. Ganz, R., Parvizi, J., Beck, M., Leunig, M., Notzli, H., Siebenrock, K.: Femoroacetabular impingement: a cause for osteoarthritis of the hip. *Clin Orthop Rel Res* **417**, 112–120 (2003)
11. Gilles, B., Kolo-Christophe, F., Magnenat-Thalmann, N., Becker, C., Duc, S., Menetrey, J., Hoffmeyer, P.: MRI-based assessment of hip joint translations. *J Biomech* **42**(9), 1201–1205 (2009)
12. Gilles, B., Moccozet, L., Magnenat-Thalmann, N.: Anatomical modelling of the musculoskeletal system from MRI. In: R. Larsen, M. Nielsen, J. Sparring (eds.) *MICCAI 2006, LNCS*, vol. 4190, pp. 289–296. Springer-Verlag (2006)
13. Gilles, B., Perrin, R., Magnenat-Thalmann, N., Valle, J.P.: Bones motion analysis from dynamic MRI: acquisition and tracking. *Acad Radiol* **12**, 2385–2392 (2005)
14. Groh, M., Herrera, J.: A comprehensive review of hip labral tears. *Curr Rev Musculoskelet Med* **2**, 105–117 (2009)
15. Ito, K., 2nd, M.M., Leunig, M., Werlen, S., Ganz, R.: Femoroacetabular impingement and the cam-effect: a MRI based quantitative anatomical study of the femoral headneck offset. *J Bone Joint Surg Br* **83**, 171–176 (2001)
16. Lavigne, M., Parvizi, J., Beck, M., Siebenrock, K., Ganz, R., Leunig, M.: Anterior femoroacetabular impingement: Part I: Techniques of joint preserving surgery. *Clin Orthop Rel Res* **418**, 61–66 (2004)
17. Leunig, M., e, P.B., Ganz, R.: The concept of femoroacetabular impingement. *Clin Orthop Rel Res* **467**, 616–622 (2009)
18. Lewis, C., Sahrman, S.: Acetabular labral tears. *Phys Ther* **86**, 110–121 (2006)
19. Mason, J.: Acetabular labral tears in the athlete. *Clin J Sport Med* **20**, 779–790 (2001)
20. McCarthy, J., Noble, P., Aluisio, F., Schuck, M., Wright, J., Lee, J.: Anatomy, pathologic features, and treatment of acetabular labral tears. *Clin Orthop Rel Res* **406**, 38–47 (2003)
21. McCarthy, J., Noble, P., Schuck, M., Wright, J., Lee, J.: The otto E. Aufranc Award: the role of labral lesions to development of early degenerative hip disease. *Clin Orthop Rel Res* **393**, 25–37 (2001)
22. N, N.S., Villar, R.: Acetabular labral tears: result of arthroscopic partial limbectomy. *Arthroscopy* **16**, 11–15 (2000)

23. Nötzli, H., Wyss, T., Stöcklin, C., MR, M.S., Treiber, K., Hodler, J.: The contour of the femoral headneck-junction as a predictor for the risk of anterior impingement. *J Bone Joint Surg Br* **84**, 556–560 (2002)
24. Pfirrmann, C.W.A., Mengiardi, B., Dora, C., Kalberer, F., Zanetti, M., Hodler, J.: Cam and pincer femoroacetabular impingement: Characteristic MR arthrographic findings in 50 patients. *J Radiol* **240**(3), 778–785 (2006)
25. Reynolds, D., Lucas, J., Klaue, K.: Retroversion of the acetabulum. a cause of hip pain. *J Bone Joint Surg* **81**(2), 281–288 (1999)
26. Schmid, J., Magnenat-Thalmann, N.: MRI bone segmentation using deformable models and shape priors. In: D. Metaxas, L. Axel, G. Szekely, G. Fichtinger (eds.) MICCAI 2008, Part I. LNCS, vol. 5241, pp. 119–126. Springer-Verlag (2008)
27. Siebenrock, K., Schniger, R., Ganz, R.: Anterior femoroacetabular impingement due to acetabular retroversion and its treatment by periacetabular osteotomy. *J Bone Joint Surg Am* **85**, 278–286 (2003)
28. Tannast, M., Goricki, D., Beck, M., Murphy, S.B., Siebenrock, K.A.: Hip damage occurs at the zone of femoroacetabular impingement. *Clin Orthop Rel Res* **466**, 273–280 (2008)
29. Website: Berkeley db xml (Accessed January 2010). URL <http://www.oracle.com/database/berkeley-db/index.html>
30. Website: Protégé (Accessed January 2010). URL <http://protege.stanford.edu/>
31. Website: Visual toolkit (Accessed January 2010). URL <http://www.vtk.org/>
32. Wu, G., Siegler, S., Allard, P., Kirtley, C., Leardini, A., Rosenbaum, D., Whittle, M., D’Lima, D., Cristofolini, L., Witte, H., Schmid, O., Stokes, I.: ISB recommendation on definitions of joint coordinate system of various joints for the reporting of human joint motion - part i: Ankle, hip and spine. *J Biomech* **35**(4), 543–548 (2002)