

ArthroPlanner: A Surgical Planning Solution for Acromioplasty

C. Charbonnier¹, S. Chagué¹, B. Kevelham¹, F.C. Kolo,² A. Lädermann³

¹ Medical Research Department, Artanim Foundation, Geneva, Switzerland

² Rive Droite Radiology Center, Geneva, Switzerland

³ Division of Orthopedics and Trauma Surgery, La Tour Hospital, Meyrin, Switzerland and Faculty of Medicine, University of Geneva, Geneva, Switzerland

Purpose

Subacromial impingement of the rotator cuff between the anterior [1] or lateral [2] acromion and the superior humeral head is a common disorder. This condition arises when the subacromial space height is too narrow during active elevation or scaption of the arm above shoulder level due to an abnormal hooked shape or large lateral extension of the acromion.

In severe cases of impingement syndrome, an arthroscopic acromioplasty surgery is usually performed to resect the different areas of the acromion causing damage to the subacromial structures. The exact location and the amount of bone to be resected is generally left to the unique appreciation of the orthopedic surgeon during surgery. To improve the precision of this resection, surgeons could greatly benefit from a surgical planning solution that aims at providing precise information about the surgical procedure. Moreover, since subacromial impingements are the result of a dynamic mechanism, an effective planning solution should analyze both the morphological joint's structures and its dynamic behavior during shoulder movements to fully apprehend the patient joint's condition.

We present our computer-assisted planning solution "ArthroPlanner" for acromioplasty. The solution allows to perform standard morphological bony measurements, as well as 3D simulations of the patient's joint during everyday shoulder activities. The software computes the precise bone resection (location and amount) based on detected subacromial impingements during motion.

Methods

We reconstruct the bones of the patient's shoulder joint (scapula and humerus) from a CT image using Mimics software. The bones are then imported into ArthroPlanner software and the following steps are performed:

First, biomechanical parameters are computed. The glenohumeral joint center is calculated by a sphere fitting technique [3] (Fig. 1A). Bone coordinate systems are established for the scapula and humerus (Fig. 1B) based on ISB [4] using anatomical landmarks defined on the bone models and CT image.

Second, motion is applied at each time step to the humerus model with real-time evaluation of impingement. The minimum humero-acromial distance [5] is calculated based on the simulated bones models positions. A color scale is used to map the variations of distance on the scapula surface (red color = minimum distance, other colors = areas of increased distance). Given the thickness of the

potential impinged tissues, subacromial impingement is considered when the computed humero-acromial distance is < 6 mm [5]. To test a wide variability of realistic movements, a motion database of daily activities (e.g., cross arm, comb hair) is used in addition to standard kinematic sequences (e.g., elevation, scaption).

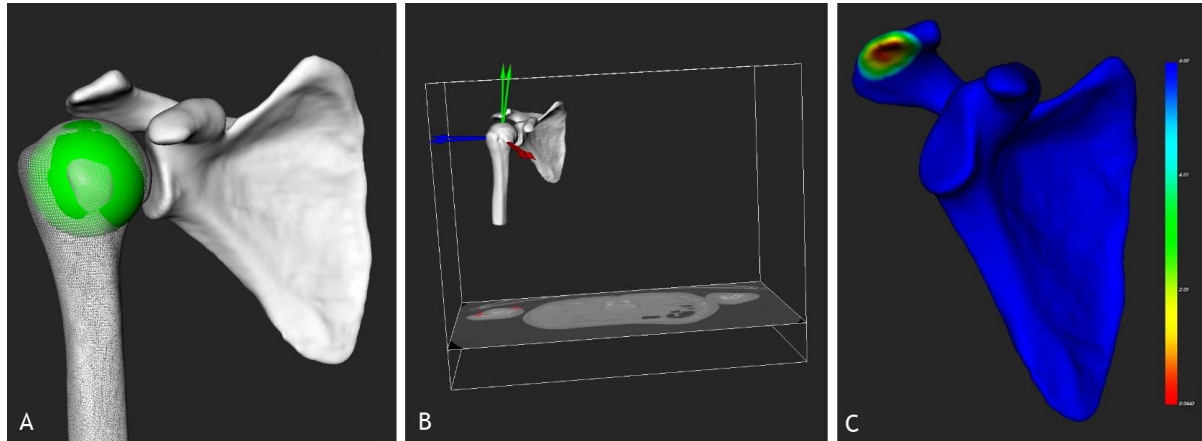


Fig. 1: A) Glenohumeral center computation, B) bone coordinates systems computation and C) acromial resection plan.

Third, the acromial resection plan is defined based on the 3D simulation results. A color map is used to represent areas where impingements occurred between the acromion and humerus (Fig. 1C). The red color denotes the area with the smallest humero-acromial distance computed over the different motion simulations.

A PDF report is finally generated that contains patient's information and the measurements performed. The bones and the simulation data are also exported to be used in a simple 3D viewer dedicated to the surgeon (Fig. 2). With this viewer, the surgeon is able to play all simulations, observe impingements dynamically and review the resection plan.

Results

To test the validity of the planning solution, a clinical study is performed with 67 patients undergoing acromioplasty by an experienced orthopedic surgeon. 3D reconstruction and preoperative planning were performed for all patients. However, the surgeon could review the results of the planning for 32 patients only, the other 35 were part of the control group. The software showed significant robustness in performing the different planning steps and provided intra-patient reproducible results. One planning with the 3D reconstruction took in average 45 minutes, which is feasible in the clinical routine. The surgeon reported that the planning changed completely his way to handle the surgery. He has decreased the number of anterior acromioplasties, and is performing more lateral and posterior bony resections.

Post-operative visits for all patients will be performed at 6 months and 1 year after surgery, including a clinical examination (evaluation of the ranges of motion, pain scores) and an echography to control the rotator cuff. A post-operative CT 3D reconstruction will also be performed to determine the actual bone resection executed at surgery compared to the planning recommendations. The data collected will be compared between the groups.

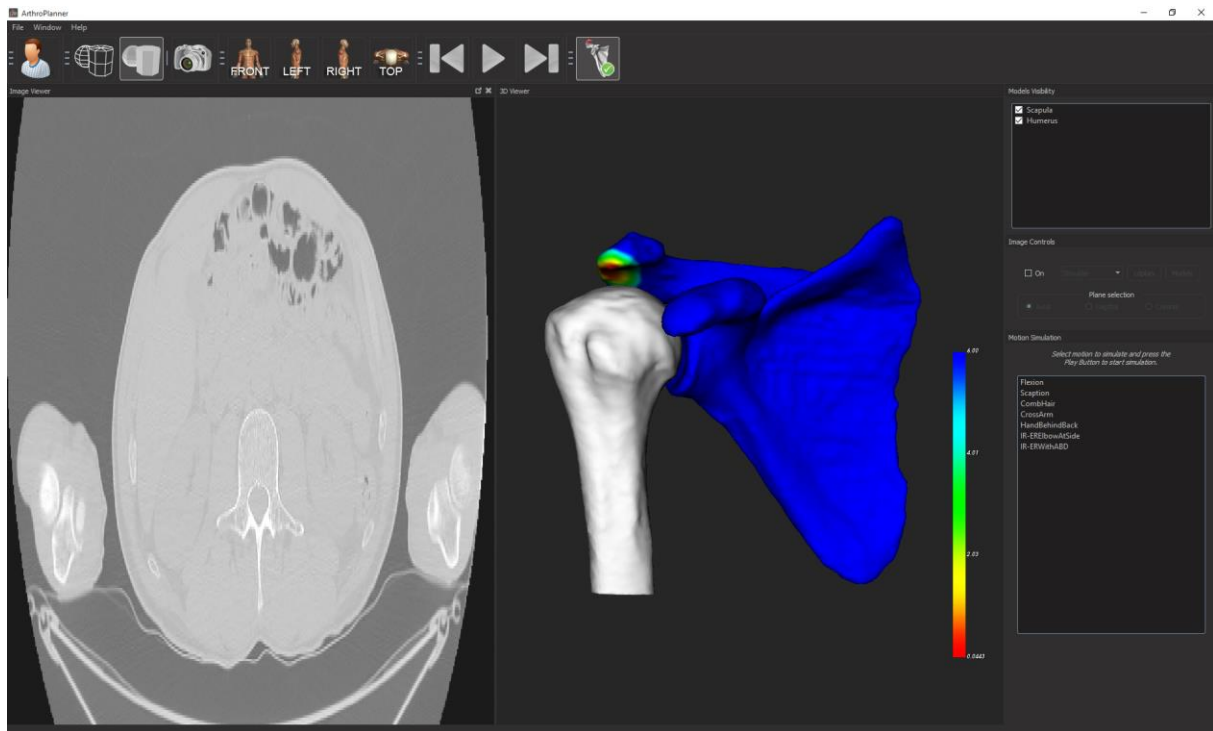


Fig. 2: 3D viewer with the simulation and visualization tools.

Conclusions

We presented a computer-assisted solution for acromioplasty. The software allows surgeons to better plan the surgical procedure by visualizing dynamic simulation of the patient's shoulder joint during everyday activities. Impingements are dynamically detected and the exact location and amount of bone to be resected is precisely computed. As a result, the success of the acromioplasty does not only rely on the surgeon's experience, but on quantitative data.

Although the clinical validation of the planning solution is currently under evaluation, we expect that it will allow patients to recover more effectively postoperative joint mobility, get a better relationship with pain and a better healing rate of the rotator cuff tendons.

References

- [1] Neer CS, 2nd. Anterior acromioplasty for the chronic impingement syndrome in the shoulder: a preliminary report. *J Bone Joint Surg Am.* 54(1):41-50, 1972.
- [2] Nyffeler RW, Werner CM, Sukthankar A, et al. Association of a large lateral extension of the acromion with rotator cuff tears. *J Bone Joint Surg Am.* 88(4):800-805, 2006.
- [3] Schneider P, Eberly D. Geometric tools for computer graphics. The Morgan Kaufmann Series in Computer Graphics and Geometric Modeling, 2003.
- [4] Wu G, van der Helm F, Veegerc H, et al. ISB recommendation on definitions of joint coordinate systems of various joints for the reporting of human joint motion - Part II: shoulder, elbow, wrist and hand. *J Biomech,* 38(4):981-992, 2005.

[5] Charbonnier C, Chagué S, Kolo FC, Lädermann A. Shoulder Motion During Tennis Serve: Dynamic and Radiological Evaluation Based on Motion Capture and Magnetic Resonance Imaging. *Int J CARS*, 10(8):1289-1297, 2015.